

CASE REPORT



Bilaterally impacted mandibular fourth molar – A rare case report and review of literature

Raj Merchant, Imran Khalid, Vani Mehrotra

Department of Oral and Maxillofacial Surgery, MGM Dental College and Hospital, Navi Mumbai, Maharashtra, India

Correspondence:

Dr. Raj Merchant, Department of Oral and Maxillofacial Surgery, MGM Dental College and Hospital, Navi Mumbai, Reside at 33, Shirin Manzil, 4th floor, Shrikant Palekar Road, Chira Bazaar, Mumbai, Maharashtra, India. Email: merchantraj786@gmail.com

Received 15 February 2019;

Accepted 30 March 2019

doi: 10.15713/ins.ijmdcr.114

How to cite the article:

Merchant R, Khalid I, Mehrotra V. Bilaterally impacted mandibular fourth molar – A rare case report and review of literature. Int J Med Dent Case Rep 2018;5:1-3.

Abstract

Panoramic radiographs of male patient revealed the presence of bilateral impacted fourth molars in mandibular region. The supernumerary teeth were distomolars and had normal tooth morphology with regard to their crowns and roots but were slightly smaller than the existing third molars. Their crowns were three tuberculate and they all had single roots. Supernumerary teeth are often located in the anterior maxilla, mandible, and to a lesser frequency posterior of the maxillary and mandibular region. They are classified as distomolar when they are located in posterior to their location. Their presence may or may not give rise to a variety of clinical problems. Detection of supernumerary teeth is usually achieved by clinical and radiographic examination. Their management should form part of a comprehensive treatment plan. A fourth molar tooth is a very rare entity in modern humans although prevalent in early humans. This article presents a case report in a non-syndromic patient with bilateral impacted mandibular distomolar; aberrations associated with supernumerary teeth and also a note on their incidence and prevalence.

Keywords: Bilateral fourth molar, distomolar, mandibular wisdom teeth, supernumerary teeth

Introduction

There are 20 deciduous and 32 permanent teeth. Any tooth in excess than its usual configuration of the normal number of deciduous or permanent teeth is termed as hyperdontia. It can be single or multiple, unilateral or bilateral, and upper or lower jaw.^[1-3]

Supernumerary teeth have been reported in various region of the dental arch, but more frequently they are observed in maxillary arch and can occur in both primary and permanent dentition. The prevalence of these teeth for permanent and primary dentition in various populations is between 0.5–5.3% and 0.2–0.8%.^[2]

Supernumerary teeth are classified as follows: (a) According to their position in the dental arch as mesiodens, paramolar, and distomolar; (b) according to their shape, they can be further classified as conical, tuberculate, molariform, and supplemental;^[1] (c) according to primosch, they can be classified as supplementary/eumorphic – teeth with normal shape and size or rudimentary/dysmorphic – tooth with abnormal shape and size.^[4-5]

The occurrence of bilateral distomolar teeth is only 0.07% of population.^[6] Cases of bilateral mandibular fourth molars with normal morphology have rarely been reported in the dental literature, particularly distomolar.^[7] This paper reports a case

of additional eumorphic bilateral impacted fourth molars or distomolars in mandibular region in non-syndromic patient.

Case Report

A 27-year-old male patient reported to the Department of Oral and Maxillofacial Surgery, MGM Hospital and School of Dental Sciences, with a chief complaint of intermittent recurrent pain in the right lower jaw for 3 months. The pain as gradual in onset, moderate in nature, dull in intensity, and radiating in toward left ear region, aggravated during mastication and relieved during rest. He also gives history of similar intermittent pain in the region of left lower third molar two years back, which he mentions relieved with oral analgesics and antibiotics prescribed by family physician; however, no dental investigation or treatment was taken. He denies fever, swelling or pus discharge. He had no history of any other systemic diseases or other medical or surgical history.

On clinical examination, there were bilateral pericoronitis and food lodgement in the bilateral lower third molar region, proximal caries with right third molar, deep occlusal caries with the left 3rd molar pain on percussion was present with the right third molar region, silver amalgam fillings with the right 1st molar and 1st premolar teeth, left 1st molar was missing, and occlusal caries with upper right 3rd molar. Based on clinical

examination, provisional diagnosis was acute reversible pulpitis with the right 3rd molar and chronic irreversible pulpitis with upper right 3rd molar and lower left 3rd molar. No abnormalities were detected in temporomandibular joint region and mouth opening was 34 mm. Oculoplethysmography (OPG) and blood investigations were advised for further evaluation.

The radiographic findings on the OPG [Figure 1] showed bilateral distomolars impacted in mandibular third molar region and his blood investigations were within normal limits.

Plan of action was surgical extraction of impacted mandibular distomolars followed by root canal treatment with upper and lower 3rd molars and left 3rd molar and prosthetic rehabilitation with the left 1st molar. Condition, treatment plan as well as risk and complications related to extraction explained to the patient.

Informed consent was taken. Surgical extraction of impacted right mandibular third distomolar was done under anesthesia with all aseptic precautions. Procedure was uneventful.

Following the procedure, antibiotics and anti-inflammatory prescribed and the patient advised to follow-up after 5 days or earlier if any complications.

Discussion

The incidence of the hyperdontia molars is reported 1% by Stafne;^[8] as 2% by Luten,^[9] and 1.9% by Backmann^[10] and is higher in males than in females.^[11] The etiology is still unclear; however, there are various theories such as phylogenetic theory, the tooth germ dichotomy theory, and the hyperactivity of the dental lamina. The hyperactivity of dental lamina is widely accepted theory.^[1-2]

Of their frequency in the dental arch, they are listed as follows – maxillary midline supernumeraries (mesiodens), maxillary fourth molars, maxillary paramolars, mandibular premolars, maxillary lateral incisors, mandibular fourth molars, and maxillary premolars.^[12]

They are commonly seen in association with the disease or syndrome; occurrence of it without any other associated disease or syndrome is rare in individuals.^[5] In the present case, bilateral impacted supernumerary fourth distomolar in mandible was detected in non-syndromic patient. Bilateral mandibular

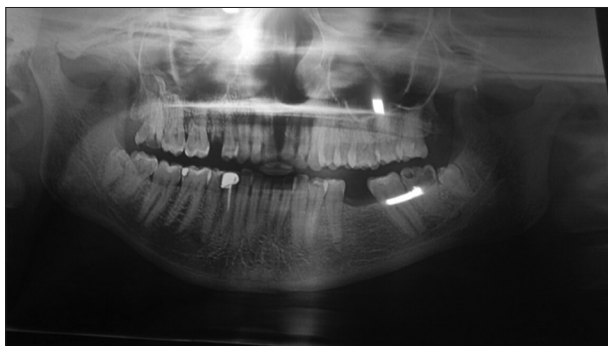


Figure 1: Oculoplethysmography showing bilateral impacted mandibular fourth molar

distomolar cases are very rare, and by far as per my knowledge, only two cases have been reported in literature. Their incidence is rare with only a 0.02% reported in the mandible.^[13-14]

Treatment depends on the type and location of the supernumerary teeth and on its potential effect on adjacent hard and soft tissue structures in conjunction with the clinical findings;^[11,12] however, the management of such patients is challenging as its treatment plans are debated whether to extract them or observe them to avoid damage to critical structures such as buccal, lingual, and distal bone surrounding the third molar; the periodontium on the distal surface of the second molar; and the neurovascular content of the mandibular canal and the lingual nerve during extraction of third molar and supernumerary tooth.

In our case, as the patient had recurrent intermittent complain of pain and food lodgement for 3 months, surgical extraction of impacted bilateral mandibular distomolar would result in better outcome. Procedure was uneventful and the patient was comfortable after extraction of the bilateral third and fourth molars.

It is to be noted that the left side molars were asymptomatic; still, their extraction was done as the patient had pericoronitis. Dodson considers the term “asymptomatic” ambiguous and insufficient as the absence of symptoms does not equal the absence of disease.^[11]

Although the extraction of the supernumerary teeth can resolve multiple associated problems, its appropriate management should be considered carefully depending on the clinical condition, risk and benefits of the procedure, and the willingness of the patient.

Conclusion

The presence of bilateral fourth molar in mandibular arch distal to the third molar is not very common; hence, an interesting dental anomaly that a dentist may encounter in their practice. Therefore, awareness of the condition, and its incidence and management are necessary.

References

1. Garvey MT, Barry HJ, Blake M. Supernumerary teeth an overview of classification, diagnosis and management. *J Can Dent Assoc* 1999;65:612-6.
2. Díaz A, Orozco J, Fonseca M. Multiple hyperodontia: Report of a case with 17 supernumerary teeth with non syndromic association. *Med Oral Patol Oral Cir Bucal* 2009;14:E229-31.
3. Rajab LD, Hamdan MA. Supernumerary teeth: Review of the literature and a survey of 152 cases. *Int J Paediatr Dent* 2002; 12:244-54.
4. Primosch RE. Anterior supernumerary teeth assessment and surgical intervention in children. *Pediatr Dent* 1981;3:204-15.
5. Gündüz K, Muğlali M. Non-syndrome multiple supernumerary teeth: A case report. *J Contemp Dent Pract* 2007;8:81-7.
6. Arslan A, Altundal H, Ozel E. The frequency of distomolar teeth in a population of urban Turkish adults: A retrospective study. *Oral Radiol* 2009;25:118-22.
7. Costantino A, Fonseca GM, Cantín M. Bilateral mandibular

- fourth molars: A case report. *Rev Stomatol Chir Maxillofac Chir Orale* 2015;116:312-4.
8. Stafne EC. Supernumerary teeth. *Dent Cosmos* 1935;74:653-9.
 9. Luten JR. The prevalence of supernumerary teeth in primary and mixed dentitions. *J Dent Child* 1967;34:346-53.
 10. Regezi JA, Sciubb JJ. *Text Book of Oral Pathology*. 2nd ed. Philadelphia, PA: W.B. Saunders Co.; 1993.
 11. Robert LA, Watts ES. Dental development in apes and humans. *J Hum Evol* 1992;22:149-53.
 12. Nordendram A. 4th and 5th molars in ramus mandibula: Casa report. *Odont T* 1968;76:23-5.
 13. Goaz PW, White SC. *Oral Radiology*. 2nd ed. Now York: The C. V. Mosby Co.; 1987.
 14. Ohata H, Hayashi K, Iwamoto M, Muramatsu K, Watanabe A, Narita M, *et al.* Three cases of distomolars. *Bull Tokyo Dent Coll* 2013;54:259-64.

This work is licensed under a Creative Commons Attribution 4.0 International License. The images or other third party material in this article are included in the article's Creative Commons license, unless indicated otherwise in the credit line; if the material is not included under the Creative Commons license, users will need to obtain permission from the license holder to reproduce the material. To view a copy of this license, visit <http://creativecommons.org/licenses/by/4.0/> © Merchant R, Khalid I, Mehrotra V. 2018