

CASE REPORT



Displacement of impacted third molar into maxillary sinus and its removal through Caldwell-Luc approach - A case report

Muhammad Mumtaz¹, Farhat Kazmi², Almuhanad Abdullah Alsuwaiket³, Majed AlGhamdi⁴

¹Specialist Oral and Maxillofacial Surgeon, Department of Dentistry, King Salman bin Abdul Aziz Hospital, Ministry of Health, Riyadh Kingdom of Saudi Arabia, ²Department of Dentistry, Oral Diagnosis/Oral Pathology, College of Dentistry, Princess Nourah Bint Abdulrahman University, Riyadh, Kingdom of Saudi Arabia, ³Department of Dentistry, King Salman bin Abdul Aziz Hospital, Ministry of Health, Riyadh Kingdom of Saudi Arabia, ⁴Department of Dental Department, King Salman bin Abdul Aziz Hospital, Ministry of Health, Riyadh, Kingdom of Saudi Arabia

Correspondence

Dr. Muhammad Mumtaz, Department of Dentistry, King Salman bin Abdul Aziz Hospital, Ministry of Health, Riyadh Kingdom of Saudi Arabia. Phone: +009660549460477. Email: mumtazmaxfac@gmail.com

Received 12 January 2019;
Accepted 18 February 2019

doi: 10.15713/ins.ijmdcr.110

How to cite the article:

Mumtaz M, Kazmi F, Alsuwaiket AA, AlGhamdi M. Displacement of impacted third molar into maxillary sinus and its removal through Caldwell-Luc approach - A case report. *Int J Med Dent Case Rep* 2018;5:1-4.

Abstract

Tooth impaction is a pathological situation where a tooth is unable to achieve its normal functional position within the expected time span. Third molars are most frequently impacted teeth. Worldwide surgical/nonsurgical removal of the third molar is the most common procedure performed by oral surgeons and dental surgeons. The removal may be associated with intra- or post-operative complications. We present a case of impacted maxillary third molar which accidentally displaced into left maxillary sinus during its removal in a 27-year-old female who reported to our department with the complaint of pain and swelling of the left side of the face. The patient was admitted and the tooth was removed from maxillary sinus through Caldwell-Luc approach.

Keywords: Caldwell-Luc approach, impaction, maxillary sinus, maxillary third molar

Introduction

Impaction of teeth especially third molars is a commonly seen phenomenon. Multiple local and systemic factors contribute when there is an impaction of the tooth.^[1] Literature reports that the prevalence of third molar impactions ranges from 16.7% to 68.6%.^[2] The prevalence of impacted third molar teeth in a sample of the Saudi population in Jeddah is estimated at 19.2%.^[3]

The removal of impacted third molars is usually the most frequently performed surgical procedure in the dental practice. According to literature, the complication rates associated with third molar removal varies from 2.6% to 30.9%, depending on multiple factors such as location, depth, and angulation of impacted tooth.^[4]

The most common complications associated with removal of maxillary third molars are fracture of tuberosity, tooth root fracture, perforation of the maxillary sinus, and prolapse of the buccal fat pad, whereas rare complications are displacement into the maxillary sinus, infratemporal fossa, and pterygopalatine fossa.^[5]

The maxillary sinus is a triangular pyramid-like cavity in the maxillary body being the widest paranasal cavity. The maxillary

sinus is present in close proximity with the apexes of the upper molars and premolars.^[6]

Tooth displacement into the maxillary sinus is a rare event, and only 0.6%–3.8% of frequency is reported in literature.^[7] This report describes an unusual case of an impacted maxillary third molar that was accidentally displaced into the maxillary sinus during extraction.

Case Report

A 27-year-old female was referred to the Department of Oral and Maxillofacial surgery, King Salman Hospital with a complaint of pain and swelling in the left maxillary region since 1 week. The pain was dull, intermittent, radiating toward the left side of face and head. The pain was rated as six on a 7-point ordinal Likert scale. The patient was fit with no significant medical illness.

Her dental history revealed that patient went for the removal of impacted maxillary left third molar tooth but was displaced into maxillary sinus during its surgical removal attempt 1 week ago. The wound was closed primarily and the case was referred

Table 1: Different medications used with frequency and dosage

Medications		
Pre-operative	Per-operative	Post-operative
Injection Cefradine 500 mg IV 8 hourly	Injection Hydrocortisone 100 mg IV stat	Injection Cefradine 500 mg IV 8 hourly 2/7
Injection Metronidazole 5 mmg IV 8 hourly		Injection Metronidazole 5 mmg IV 8 hourly 2/7
Injection Acetaminophen 500 mg IV 6 8 hourly		Injection Acetaminophen 500 mg IV 6 8 hourly 2/7
		Injection Enoxaparin 40 mg s/c on 2/7
		Nasal decongestant BID 5/7

to oral and maxillofacial surgery (OMFS) clinic. General physical examination showed that the patient was well oriented in time and space, fully stable with Glasgow Coma Scale 15/15. Patient was admitted to the ward and started the medications [Table 1]. On extraoral examination, facial asymmetry was present on left side of the face with normal mouth opening. Intraoral examination showed missing left maxillary third molar with primary closure of the overlying mucosa. There were also missing premolars and molars in both upper and lower jaw. Pre-operative panoramic radiograph was taken from a patient's file which showed multiple impacted teeth in the upper and lower jaw [Figure 1]. New post-operative panoramic radiograph was taken which revealed, the presence of maxillary third molar in either maxillary sinus or the infra-temporal fossa of left side [Figure 1].

Computed tomography (CT) scan without IV contrast advised to see the exact location of the tooth, and it confirmed the presence of tooth in left maxillary sinus [Figure 2].

Surgical procedure along with the type of anesthesia, complications of the procedure, stay in the hospital, and post-operative follow-up was discussed with the patient. As per patient consent, it was decided to do the procedure under general anesthesia. Caldwell-Luc approach was opted. Left side buccal sulcus incision was given, and the window was created in the anterior wall of left maxillary sinus [Figure 3].

Displaced tooth was taken out, and the wound was closed primarily. As per patients request and consent, mandibular bilateral impacted teeth were also removed prophylactically. The patient was kept on antibiotics, anti-inflammatory, and painkillers for 2 days postoperatively and then was discharged on oral medications [Table 1]. Post-operative X-ray done which showed maxillary sinus is free from displaced tooth [Figure 4].

Discussion

An impacted tooth fails to achieve its normal functional position due to abnormal positioning of the tooth or lack of proper space. It is observed that the most common impacted teeth are mandibular third molar, followed by maxillary third molars, maxillary canines, mandibular premolars, and then incisors. Usually, third molars erupt between the ages of 17 and 21 years and most frequently symptomatic impactions are presented at presented with an age range between 20 and 30 years.^[8] In the present case, patient presented with maxillary third molar at the age of 27 with a history of repeated episodes of pericoronitis.

Although removal of fully erupted maxillary, the third molar is a safe and simple procedure, at the same time, they are difficult

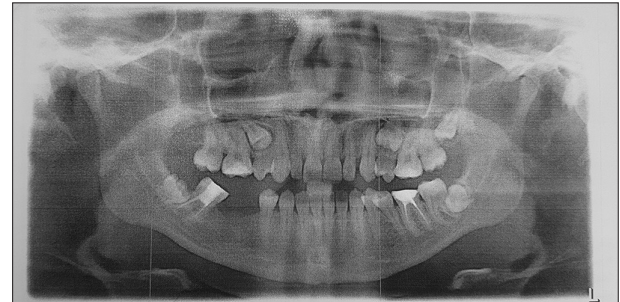


Figure 1: Pre-operative orthopantomogram showing impacted left side maxillary third molar with other multiple impacted teeth in both upper and lower jaw before extractions (a)

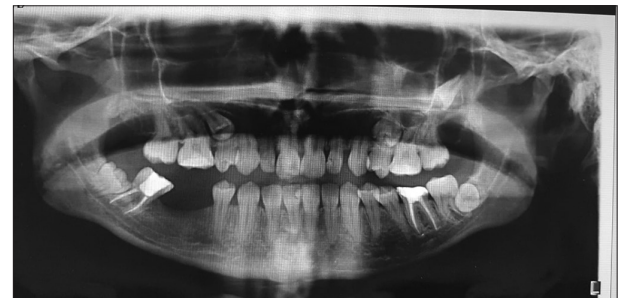

Figure 2: Post-operative orthopantomogram shows that left maxillary third impacted tooth has been displaced superiorly after surgical extraction attempt under local anesthesia

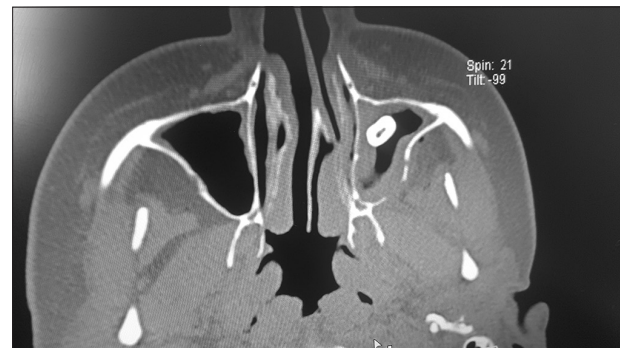

Figure 3: Axial view of computed tomography scan showing that tooth has been displaced in left maxillary sinus

to extract when they are impacted and placed superiorly, due to their anatomical relationship between the floor of the maxillary sinus, maxillary tuberosity, and infratemporal fossa.^[9] As per

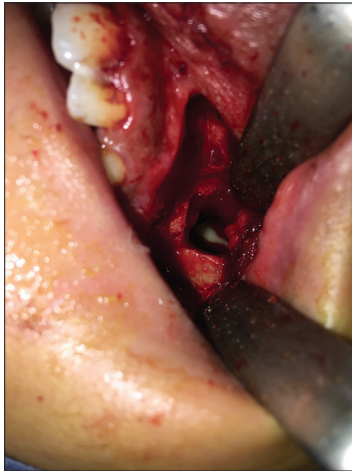

Figure 4: Caldwell-Luc approach done showing the presence of tooth in the left maxillary sinus

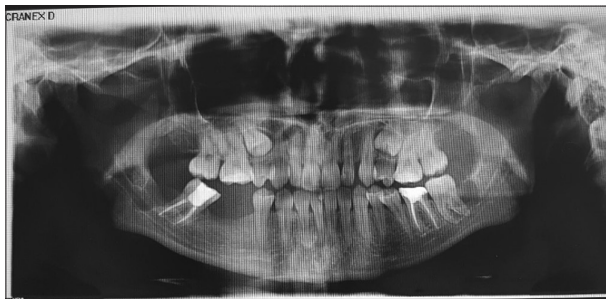


Figure 5: Post-operative X-ray shows removal of maxillary third molar of the left side, removal of mandibular left third molar, and removal of mandibular right third molar

literature, surgically removal of maxillary third molar may cause complications such as fracture of tuberosity, dislodgement of teeth into maxillary sinus, infratemporal fossa, pterygopalatine fossa, subconjunctival hemorrhage, and fracture of maxillary tuberosity [Figure 5].

The present case had a complication of displacement of the tooth into the maxillary sinus during its removal. In the present case, panoramic X-ray and CT were used to determine with precision the location of the displaced tooth. However, in some cases, the procedure can be completed with only panoramic X-rays.

The time span for the removal of the displaced tooth is quite controversial in the literature. Few researchers suggest that the displaced tooth should be removed immediately as there are risks for infection, foreign body reaction, and due to its anatomic location which can lead to the potential for morbidity.^[10]

The established treatment in case of the displaced tooth is its surgical removal, to prevent future complications. It is stated that in first place retrieval of the tooth should be attempted by placing suction at the opening of tooth socket into the sinus. If failed in this initial attempt then the sinus should be irrigated with saline and the suction tip should be reapplied. In case this second

attempt is also unsuccessful, then further attempts should not be tried, and the patient should be put on antibiotics and nasal decongestants. Most of the researchers believe that in such cases then retrieval should be managed with either Caldwell-Luc approach or transnasal maxillary sinus surgery.^[11] In the present case, as the patient was referred to OMFS clinic after 1 week of displacement, so it was operated by Caldwell-Luc approach.

Conclusion and Clinical Significance

Accidents and complications can be seen in any surgical procedure. In case of removal of impacted maxillary molar use of proper apical force during use of elevators and correct surgical technique is very important. Moreover, radiographic interpretation regarding maxillary sinus and tooth is also necessary. Inadequate surgical skills, poor clinical and radiographical assessment may end up in these complications. One attempt should be done by high-pressure suction putting just inside the fresh opening socket wound to take the displaced tooth out from maxillary sinus, otherwise, refer the case to the maxillofacial surgeon for further management. The patient should be informed and counseled for the situation.

References

1. Alamgir W, Mumtaz M, Kazmi F, Baig MA. Cause and effect relationship between mandibular third molar impactions and associated pathologies. *Int J* 2015;3:762-7.
2. Hashemipour MA, Tahmasbi-Arashlow M, Fahimi-Hanzaei F. Incidence of impacted mandibular and maxillary third molars: A radiographic study in a Southeast Iran population. *Med Oral Patol Oral Cir Bucal* 2013;18:e140-5.
3. Jan A, Alsehaimy M, Mokhtar H, Jadu FM. Prevalence of impacted third molars in Jeddah, Saudi Arabia: A retrospective study. *J Am Sci* 2014;10:1-4.
4. Azenha MR, Kato RB, Bueno RB, Neto PJ, Ribeiro MC. Accidents and complications associated to third molar surgeries performed by dentistry students. *Oral Maxillofac Surg* 2014;18:459-64.
5. Ozer N, Uçem F, Saruhanoglu A, Yilmaz S, Tanyeri H. Removal of a maxillary third molar displaced into pterygopalatine fossa via intraoral approach. *Case Rep Dent* 2013;2013:392148.
6. Demirtas O, Harorli A. Evaluation of the maxillary third molar position and its relationship with the maxillary sinus: A CBCT study. *Oral Radiol* 2016;32:173-9.
7. Bouquet A, Coudert JL, Bourgeois D, Mazoyer JF, Bossard D. Contributions of reformatted computed tomography and panoramic radiography in the localization of third molars relative to the maxillary sinus. *Oral Surg Oral Med Oral Pathol Oral Radiol Endod* 2004;98:342-7.
8. Sasano T, Kuribara N, Iikubo M, Yoshida A, Satoh-Kuiriwada S, Shoji N, *et al.* Influence of angular position and degree of impaction of third molars on development of symptoms: Long-term follow-up under good oral hygiene conditions. *Tohoku J Exp Med* 2003;200:75-83.
9. von Arx T, Fodich I, Bornstein MM. Proximity of premolar roots to maxillary sinus: A radiographic survey using cone-beam computed tomography. *J Endod* 2014;40:1541-8.

10. Amorim Kde S, da Silva VT, da Cunha RS, Souto ML, São Mateus CR, Souza LM, *et al.* Removal of an upper third molar from the maxillary sinus. *Case Rep Dent* 2015;2015:517149.
11. Primo BT, Stringhini DJ, da Costa DJ, Rebellato NL, Scariot R. Delayed removal of maxillary third molar displaced into the maxillary sinus. *Stomatologija* 2016;18:128-32.