

## CASE REPORT



## Dentigerous cyst associated with an ectopic tooth

Ozuna Ugalde Roberto<sup>1</sup>, Álvarez Valadez Carlos Omar<sup>2</sup>, Gallegos Hernández José Francisco<sup>2</sup>, Juárez Rebollar Alejandra Giselle<sup>2</sup>

<sup>1</sup>Private Practice, Graduated of Specialty Hospital "Dr. Antonio Fraga Mouret", La Raza National Medical Center, Mexican Social Security Institute, Mexico City,

<sup>2</sup>Department of Maxillofacial Surgery, Specialty Hospital, "Dr. Bernardo Sepúlveda Gutiérrez", XXI Century National Medical Center, Mexican Social Security Institute, Mexico City

**Correspondence:**

Juárez Rebollar Alejandra Giselle,  
Department of Maxillofacial Surgery,  
Specialty Hospital, "Dr. Bernardo Sepúlveda  
Gutiérrez", Century XXI National Medical  
Center, Mexican Social Security Institute,  
Mexico City.  
E-mail: giselle\_juarez@hotmail.com

Received: 20 July 2020;

Accepted: 21 September 2020

doi: 10.15713/ins.ijmdcr.144

**How to cite the article:**

Roberto OU, Omar AVC, Francisco GHJ,  
Giselle JRA. Dentigerous cyst associated with  
an ectopic tooth. Int J Med Dent Case Rep  
2020; 7:1-3.

**Abstract**

Dentigerous cysts originate from the reduced enamel epithelium, are associated with included teeth, and are one of the most common odontogenic cysts. Most of the reported cases have been mandibular and associated with the third molar. The present case is an example of atypia of dentigerous cysts, presenting its association with a mandibular ectopic molar and also the presence of two periapical cysts. The diagnosis and treatment designed for each case and the emphasis on radiographic support for the detection of dental cysts are important since when they are associated with included teeth, their clinical appearance is not frequent, but rather as a radiographic finding.

**Keywords:** Cyst, dentigerous, ectopic, tooth

**Introduction**

Follicular or dentigerous cysts are developmental cysts, the origin of which comes from the reduced enamel epithelium. It is more frequent to locate them in the mandible and associated with an included tooth, as is the case of the third molars, they form around the crown of the tooth (starting from the amelocemental junction). In the second decade of life, however, there are many cases between the 4<sup>th</sup> and 6<sup>th</sup> decades of life with a certain predilection for the male gender.<sup>[1-3]</sup> Some theories about the formation of dentigerous cysts have been named, one of which is that it appears after the formation of the related tooth when it has already formed, and fluid accumulates between the crown of the tooth and the enamel organ; the second is that they are generated during odontogenesis, a third theory is that there is a cystic proliferation of islets in the wall of the connective tissue of the dental follicle that later joins and forms the cystic cavity surrounding the crown of the tooth and another has even been named Theory that he mentions formed from root cysts of temporary teeth that erupt the permanent teeth encompassing the germ and, therefore, remain encapsulated, causing a dentigerous cyst around the dental crown.<sup>[4,5]</sup> Clinically they are asymptomatic, although the presence of increased volume

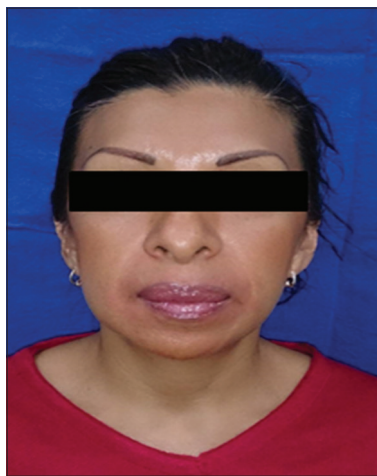or inflammation due to increased fluid in the lesion has been reported in some cases, they are usually diagnosed as a routine radiographic finding.<sup>[6]</sup> The radiological images described are generally unilocular radiolucent images associated with an included tooth.<sup>[7]</sup> The histopathological characteristics of dentigerous cysts include 2–3 thin layers of keratinized cystic epithelium, with the presence of scattered mucous cells, the capsule is usually fibrous tissue with odontogenic epithelium, and the presence of some islands or islets, inflammatory tissue may occur, and several layers of epithelium with hyperplasia. Among the risks associated with untreated or recurrent and/or persistent dentigerous cysts, its transformation to ameloblastoma has been mentioned, due to the great potential for transformation of odontogenic epithelial cell nests, another complication would be their conversion or relationship with mucoepidermoid carcinoma (in the event that any mucous cell of the lining epithelium of the cyst is associated or associated with it) and squamous cell carcinoma of the lining epithelium.<sup>[8]</sup> Dentigerous cysts are usually treated depending on the characteristics and size of the lesion; generally, they are usually enucleated, management with marsupialization has also been described in some cases. The important thing about

management is to avoid damage to adjacent structures and remnants of injury during handling.<sup>[9]</sup>

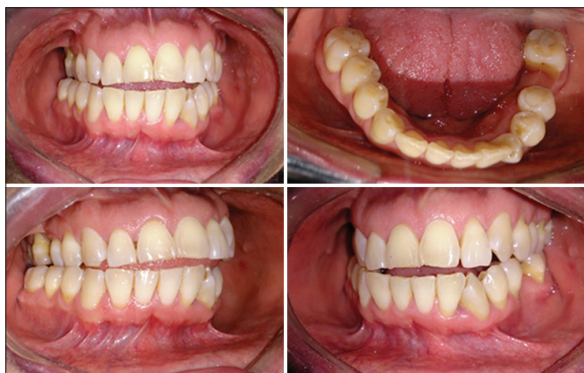**Case Report**

Female of the fifth decade of life, who goes to the Maxillofacial Surgery service of the “La Raza” IMSS Medical Center for a review, reports intermittent painful symptoms in the lower left molar region for months, not associated with any specific tooth, comes because the last 4 weeks, he has presented constant pain. Within his personal pathological history, he reported fibroadenoma in the right breast; therefore, at 27 years of age, he was excised, later he had a tendon release surgery on the right hand without referring the date of the procedure; other background denied. Clinically, without intra- or extraoral volume increase [Figures 1 and 2], incomplete secondary dentition, anterior open bite, lingual habit, and old dental restorations apparently without alteration [Figure 2] on palpation, no irregularities are found, orthopantomography is requested [Figure 3]. As a auxiliary diagnostic method, finding a mandibular radiolucent image on the left side, measuring 1.6 cm long by 1.4 cm wide in

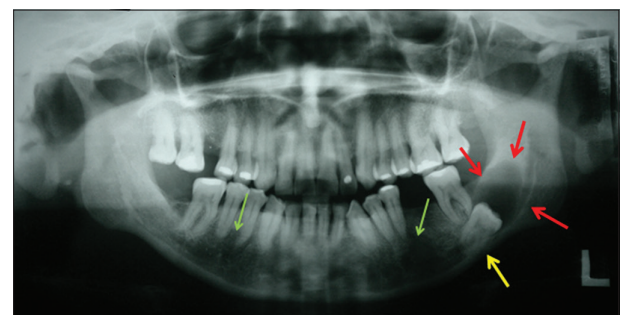
relation to the crown of tooth (ectopic molar), which is located apically of the lower left second molar, above the ipsilateral lower dental canal, also two periapical radiolucent images are observed in relation to the right and left lower premolars; it is suggested to perform treatment of the lower premolar ducts, an incisional biopsy is performed under local anesthesia, reporting heterogeneous cystic tissue with thickening, so a pre-surgical protocol is performed to perform enucleation and dental extractions of the left lower second molar and the low ectopic tooth. General anesthesia, a procedure that is carried out without complications, the pathological sample is sent to a histological study [Figure 4] reporting: In the histological sections with H&E staining with ×100 magnification, non-keratinized stratified squamous epithelium bands with 4-6 layers cells, with mucosa in some areas, covered with dense fibrous connective tissue well



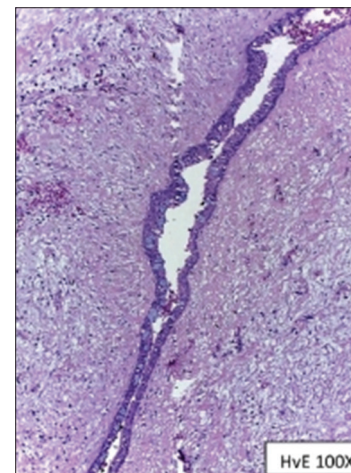
**Figure 1:** Clinical photograph, 47-year-old female patient, without extraoral volume increase



**Figure 2:** Panel of intraoral photographs, without volume increase or apparent pathological data



**Figure 3:** Orthopantomography with radiolucent area in the left mandibular molar region (red arrows) apical presence of ectopic molar in relation to second molar (yellow arrow) radiolucent areas in bilateral mandibular premolar region (green arrows)



**Figure 4:** H&E staining his photograph at ×100 magnification showing bands of non-keratinized stratified squamous epithelium with 4–6 cell layers, with mucosa in some areas, covered with dense fibrous connective tissue well vascularized with capsular appearance with some islands and atypical cell nests with some trabeculae of mature and vital lamellar bone tissue with areas of hemorrhage and chronic, slight diffuse inflammation, diagnosing as “Dentist cyst with mucosa metaplasia”

vascularized with capsular appearance with some islands and atypical cellular nests with some trabeculae of mature and vital lamellar bone tissue with areas of hemorrhage and chronic, slight diffuse inflammation, the definitive diagnosis is “dentigerous cyst with mucous metaplasia”. Clinical and radiological control is continued by the maxillofacial surgery service, with no recurrence.

## Discussion

In this case presented unlike authors such as Rajendra, Matouk and Ugurlu, who mention the association of the dentigerous cyst mainly with the third molar and its predilection for the male gender, the case that has been presented is of the female gender and associated with an ectopic that never erupted. Like Meleti and Balan, they agree on the management of dental cysts when enucleating the lesion, verifying the removal of any remnants to reduce the chances of recurrence of the lesion.

## Conclusion

Within odontogenic cysts, dentigerous cysts are among the most frequent, which are why many cases of this entity have been reported, mainly associated with included teeth such as third molars, and in some cases, mesiodens is reported, the literature mentions that dentigerous cysts are more frequent in the jaw and the male gender; associating with an ectopic tooth (as is the reported case), however, the main site of dentigerous cysts and ectopic teeth is the maxilla, so this case stands out as being an ectopic first molar. A clinical-radiographic correlation is important and timely management will have a better prognosis.

## Clinical importance

The case presented has clinical relevance since the patient was asymptomatic for many years and although dental restorations had been performed in other media, the dentigerous cyst had not been diagnosed until she went to the maxillofacial surgery service and was detected by orthopantomography, which allowed adequate treatment will be granted and the discomfort will cease. In addition to being little associated with the first lower molar, including speaking of dentigerous cysts associated with ectopic teeth, there are more reports of cases in the maxillary

or mandibular sinus in relation to the third molar. The reported case was around the crown of the first ectopic molar, hence its peculiarity.

## Acknowledgments

The participation of the service of Pathology and all the personnel that contributed is acknowledged.

## Conflict of Interests

Neither the authors nor any member has a financial or interest relationship (currently or in the last 12 months) with any entity producing, marketing, reselling, or distributing health care products or services consumed by, or used in, the patients.

## References

1. Rajendra A. Odontogenic cysts. *Dent Clin N Am* 2020;64:105-19.
2. Matouk R. A rare location for a dentigerous cyst. *Sci Arch Dent Sci* 2020;3:2-4.
3. Ugurlu F, Akyuz S, Menten A. Outcome of mandibular dentigerous cysts 1 to 10 years after decompression using a custom-made appliance. *J Oral Maxillofac Surg* 2020;2020:36.
4. Oliveira G, Siebra M, Mala N. Conservative management of a dentigerous cyst secondary to primary tooth trauma. *Dent Traumatol* 2008;24:679-9.
5. Morales D, Sánchez G, Rodríguez L. Presentación atípica de un quiste dentígero. *Rev Cubana Estomatol* 2009;46:117-26.
6. Peralta E, Peña C, Jiménez A. Diagnóstico de quiste dentígero en sacos foliculares de terceros molares incluidos. *Acta Odontol Col* 2020;10:24-36.
7. Floriam L, Danelon M, da Silva VO, Gonçalves E, Báez-Quintero L, Macchetti K. Quiste dentígero en odontología/ Cisto dentígero em odontologia/Dantigerous cyst in dentistry. *Rev Odontop Latino Am* 2019;9:160-70.
8. Meleti M, van der Waal I. Clinicopathological evaluation of 164 dental follicles and dentigerous cysts with emphasis on the presence of odontogenic epithelium in the connective tissue. The hypothesis of focal ameloblastoma. *Med Oral Patol Oral Cir Bucal* 2012;18:e60-4.
9. Balan A. Dentigerous cyst of jaws: Clinico-pathological-imaging correlations of two cases. *J Oral Med Oral Surg Oral Pathol Oral Radiol* 2019;5:132-5.

This work is licensed under a Creative Commons Attribution 4.0 International License. The images or other third party material in this article are included in the article's Creative Commons license, unless indicated otherwise in the credit line; if the material is not included under the Creative Commons license, users will need to obtain permission from the license holder to reproduce the material. To view a copy of this license, visit <http://creativecommons.org/licenses/by/4.0/> © Roberto OU, Omar AVC, Francisco GHJ, Giselle JRA. 2020